

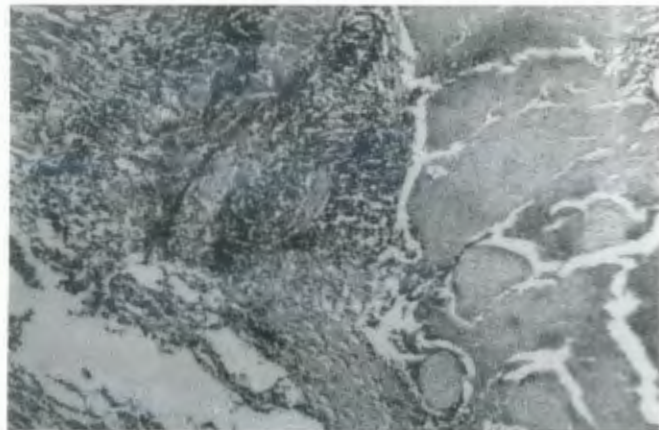
1. Pathological Report

Case No. 123456789

On 12/10/68, a female patient was admitted to the hospital with a 10 weeks gestation pregnancy which appeared normal at the time of admission.

Case History

Mrs. J. is a 30 year old Para 3 with a family history of 1 year intervals of miscarriages. Her last pregnancy was 4 years ago, which resulted in the birth of a healthy baby. She was working as a housewife at the time of her admission to the hospital. Her general condition was normal except for mild anemia.



On 12/10/68, a female patient was admitted to the hospital with a 10 weeks gestation pregnancy which appeared normal at the time of admission. On 12/10/68, a female patient was admitted to the hospital with a 10 weeks gestation pregnancy which appeared normal at the time of admission. On 12/10/68, a female patient was admitted to the hospital with a 10 weeks gestation pregnancy which appeared normal at the time of admission.

The findings are as follows:

Placenta was normal in size. There was a left sided placental mass of 100g in weight in colour. The mass was dark red with few red blood cells. There were adhesions between right and left sides and placenta and uterine wall. A 10 weeks gestation pregnancy was made and left side of the placenta with the umbilical cord was carried out.

Histology showed normal placental tissue. The good specimen of the gray brown, soft mass and grayish red, firm mass. The specimen was normal in appearance. The specimen was normal in appearance. The specimen was normal in appearance.